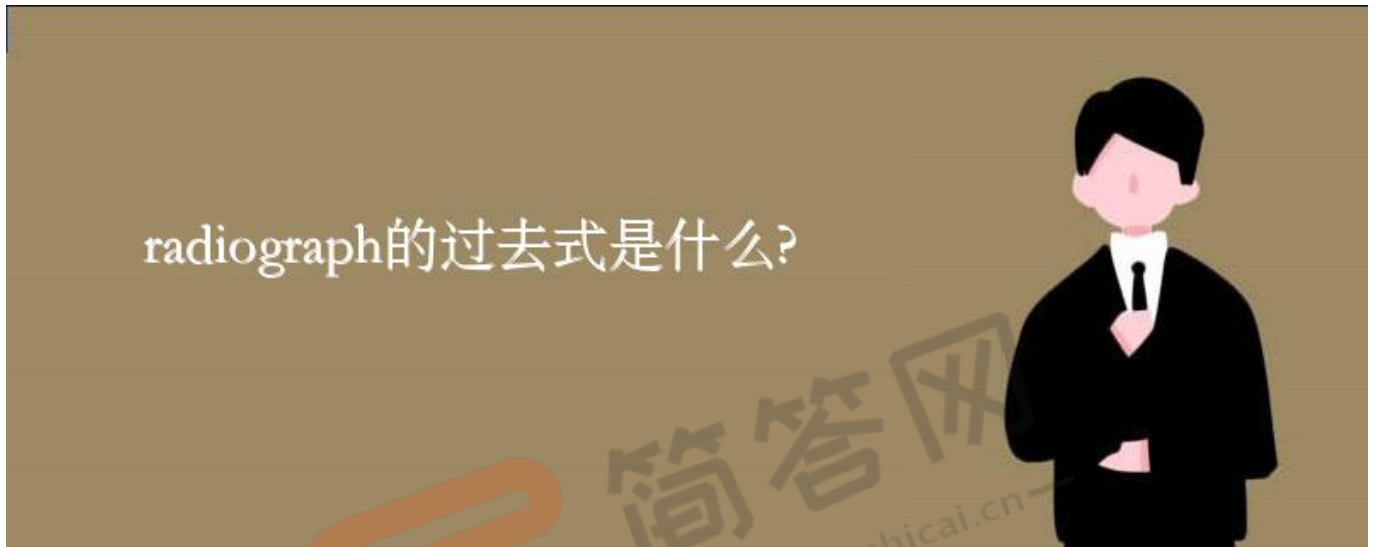


《radiograph的过去式是什么?radiograph的用法和例句》

radiograph有射线照片，X光照片;等意思，那么你知道radiograph的过去式是什么吗?今天一起来学习一下radiograph的过去式以及radiograph的用法和例句，希望对大家的学习有所帮助!



radiograph?????????

radiograph????:radiographed

radiograph????:radiographed

radiograph????:radiographing

radiograph?????:radiographs

radiograph??????

1?Bone radiograph texture measurement based on power spectrum and fractal analysis have been proposed.

????????????X? ????????????

2?Objective To research the application value of direct digital radiograph (DDR) in nasal bone imaging.

????????X? ?? (directdigitized radiography,DDR) ????????????

3?The radiograph finding of popcorn pattern of calcification occurs in fewer than 30 percent of patients.

???30%??????????????????.

4?This radiograph demonstrates a right pneumothorax. Note the displacement of the heart to the left.

????????, ??????.

5?The plain radiograph of the spine demonstrated mild scoliosis.

????????????????8?,????11?.

6?Objective Analyse the quality of oblique radiography of cervical vertebrae improve the rate of first - class radiograph.

?:?????????,?????.

7?Conclusion Patients with acute volvulus could been diagnosed early by using dynamic radiograph.

????????????????????????????????.

8?Small spring and radiograph is applied to paper, in the end.

??????,????????.

9?Conclusion application of combine digital fluoroscopy and digital radiograph in IVU is valuable.

??.

10?Objective To study the clinical effect on patientsacute volvulus in early diagnosis by using dynamic radiograph.

????????????????????????????????.